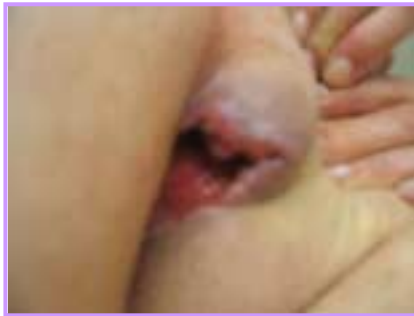
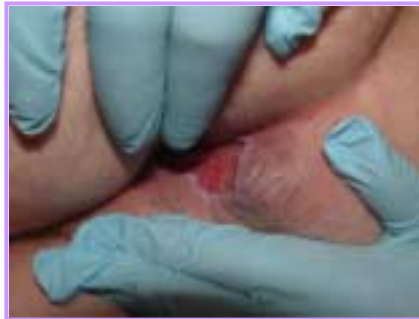
Trauma Wound - Buttocks

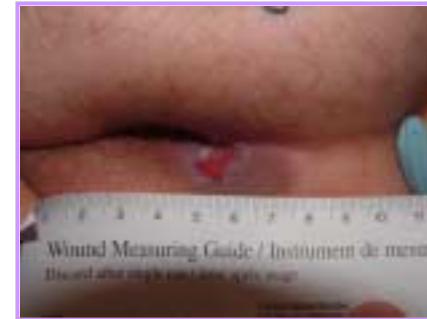45 year-old male; fell from roof and inner buttocks region impaled by metal plant hanger; muscle torn with internal tear into rectum (sutured)



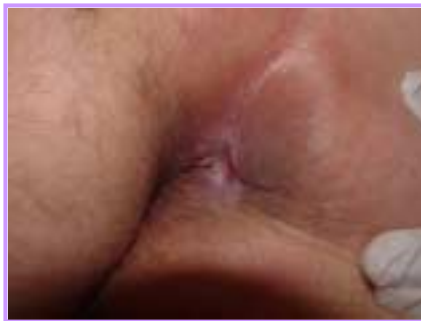Pre-EpiFLO; 3 x 2 cm;
extensive undermining



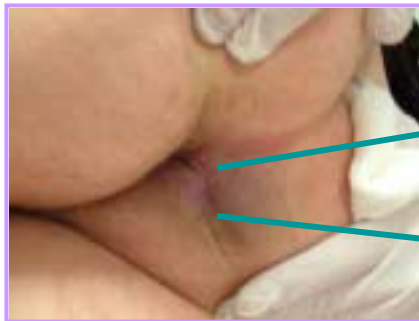
Week 1 EpiFLO; 1.5 x
2 cm; no undermining



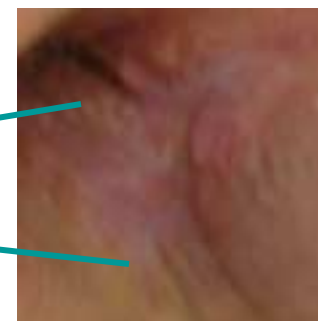Week 2 EpiFLO; 1.25
x 0.75 cm



Week 3 EpiFLO; 0.9 x
0.5 cm



Week 4 EpiFLO; Complete
healing / epithelialization



Excellent wound
healing cosmesis /
quality of healing