

# Continuous Topical Oxygen for the Treatment of Chronic Wounds: A Pilot Study

Kevin Y. Woo, PhD, RN, FAPWCA; Patricia M. Coutts, RN, IIWCC (Toronto);  
and R. Gary Sibbald, BSc, MD, MEd, FRCPC(Med Derm), MACP, FAAD, MAPWCA

## ABSTRACT

Oxygen is essential for all stages of wound healing. Previous research has shown topical administration of oxygen to have positive effects on wound healing. In this study, the application of transdermal continuous topical oxygen therapy (TCOT) was evaluated for its effect on chronic wound healing in 9 patients. After 4 weeks of treatment, mean wound surface area and wound infection checklist scores were significantly reduced. Signs of bacterial damage were also reduced. Findings from this study suggest TCOT may be beneficial in promoting chronic wound healing.

**KEYWORDS:** continuous topical oxygen, chronic wounds, oxygen and wound healing

ADV SKIN WOUND CARE 2012;25:543–547

## OXYGEN AND WOUND HEALING

Oxygen is crucial to all stages of wound healing—modulating cell migration, adhesion, proliferation, neovascularization, remodeling, and apoptosis<sup>3</sup> (Figure 1).

The key multifaceted roles of oxygen in wound healing include the following:

- *Energy metabolism.* Oxygen is the last electron acceptor for mitochondrial cytochrome oxidase leading to the production of high-energy phosphates that are required for multiple cellular functions.
- *Collagen synthesis.* Oxygen is involved in the hydroxylation of proline and lysine in procollagen, which is crucial in collagen maturation.
- *Neovascularization.* Although hypoxia is required to engender neovascularization, supplemental oxygen administration has been shown to sustain and accelerate vessel growth. Oxygen induces vascular endothelial growth factor (VEGF) mRNA levels in endothelial cells and macrophages in vivo. It may also facilitate wound contraction by triggering the differentiation of fibroblasts to myofibroblasts.
- *Antimicrobial action.* Wound tissues are susceptible to increased bacterial burden causing local wound infection under a relative hypoxic environment. Through the respiratory burst activity, oxygen is converted by leukocytic nicotinamide adenine dinucleotide phosphate oxidase to superoxide ion and other reactive oxygen species that are all lethal to bacteria.<sup>3,4</sup>

Oxygen may be relatively deficient in the wound environment because of disrupted vasculature or high energy demand during metabolic activities to support tissue regeneration. In addition, increased sympathetic outflow and circulating vasoactive stress hormones due to wound-related pain may further compromise tissue oxygenation levels at the wound surface.<sup>5</sup> According to Gordillo and Sen,<sup>6</sup> oxygen tension (PO<sub>2</sub>) was estimated to range between 0 and 10 mm Hg at the center and progressively increased to

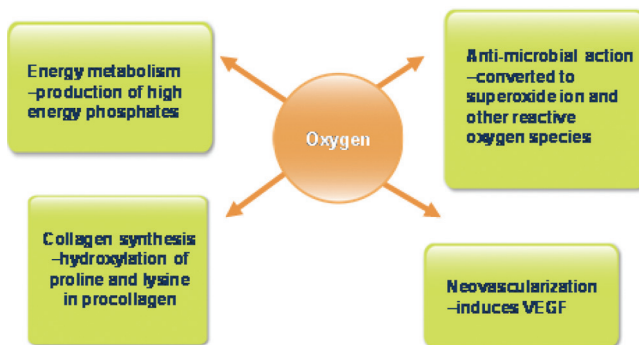
## INTRODUCTION

Normal cutaneous ulcer healing usually follows a well-orchestrated trajectory. A complex network of biochemical pathways and sequential cellular interactions ensure an integrated progression of hemostasis, inflammation, proliferation (matrix deposition), wound closure, and remodeling. Wound healing, however, is often stalled at the inflammation or proliferation stage, producing chronic wounds that do not heal at the expected rate.<sup>1</sup> Chronic nonhealing wounds are a burgeoning problem, and they constitute a significant burden for patients and the healthcare system, contributing to substantial disability (such as quality of life and activities of daily living), morbidity (such as amputations), and healthcare costs. The exact mechanisms that contribute to poor healing of ulcers are still a subject of controversy but result from both systemic and local factors.<sup>2</sup>

Accumulating evidence suggests that wound healing is dependent on local oxygen supply.

Kevin Y. Woo, PhD, RN, FAPWCA, is Assistant Professor, School of Nursing, Queen's University, Kingston, Ontario, Canada. R. Gary Sibbald, BSc, MD, MEd, FRCPC(Med Derm), MACP, FAAD, MAPWCA, is Professor of Public Health and Medicine, and Director, International Interprofessional Wound Care Course & Masters of Science in Community Health (Prevention & Wound Care), Dalla Lana School of Public Health, University of Toronto, Ontario, Canada. Patricia M. Coutts, RN, IIWCC (Toronto), is President, Canadian Association of Wound Care, and Wound Care and Clinical Trial Coordinator, Toronto Regional Wound Clinic, Mississauga, Ontario, Canada. Dr Woo has disclosed that he is/was a recipient of grant/research funding from BSN Medical, 3M, Mölnlycke, Coloplast, Gaymar, Systagenix, and Medline; is/was a consultant/advisor to BSN Medical, 3M, Gaymar, Hollister, Mölnlycke, Coloplast, Systagenix, KCI, ConvaTec, and the Registered Nurses Association of Ontario; and is/was a member of the speakers' bureau for BSN Medical, 3M, Mölnlycke, Coloplast, Hollister, Gaymar, Systagenix, and KCI. Ms Coutts has disclosed that she was a recipient of grant/research funding from Ogenix. Dr Sibbald has disclosed that he is/was a recipient of grant/research funding from BSN Medical, 3M, Mölnlycke, Coloplast, Gaymar, Johnson & Johnson (Systagenix), and KCI; is/was a consultant/advisor to BSN Medical, 3M, Gaymar, Mölnlycke, Coloplast, Gaymar, Johnson & Johnson (Systagenix), KCI, Covidien, and the Registered Nurses Association of Ontario; and is/was a member of the speaker's bureau for BSN Medical, 3M, Mölnlycke, Coloplast, Gaymar, Johnson & Johnson (Systagenix), and KCI. The authors disclose that this study received financial support from Ogenix. Submitted July 15, 2011; accepted in revised form January 12, 2012.

**Figure 1.**  
**OXYGEN IN WOUND HEALING**



approximately 60 mm Hg toward the peripheral wound margin even in wounds with adequate vasculature. Hypoxia compromises normal cellular activities and increases lactate production, leading to poor wound healing. Analysis by Heng et al<sup>7</sup> indicated that wounds were slow to heal—compounded by the accumulation of necrotic tissue and poor formation of granulation tissue if the TcPO<sub>2</sub> was measured between 13 and 30 mm Hg. Among patients with ischemic ulcers, a transcutaneous oxygen tension of more than 40 mm Hg was predictive of complete closure.<sup>8</sup> No improvement was noted in the wound condition in patients with TcPO<sub>2</sub> of less than 20 mm Hg. The key question is whether there is any merit in considering supplementary oxygen in wound management.

Studies using various forms of oxygen therapy have shown positive effects on wound healing.<sup>1</sup> Pooled data from 6 randomized controlled trials on ulcers in people with diabetes suggest a significant reduction in the risk of major amputation with hyperbaric oxygen therapy (HBOT), but there was no significant improvement in wound size reduction or the number of healed wounds.<sup>9</sup> The benefits of HBOT for other chronic wound types remain unclear. Although HBOT may be beneficial for wound healing, it should be noted that hyperoxygenation can be toxic, particularly to the brain and lungs. The requirement for patients to travel 4 to 5 times per week to the HBOT clinic for 45 to 120 minutes of therapy has rendered this treatment option less favorable in light of the transportation cost and time. As an alternative, topical oxygen has been developed. Topical oxygen can be delivered in 2 ways: intermittently or continuously. Continuous topical oxygen is also referred to as transdermal continuous oxygen therapy.

An in vivo study revealed that topically applied dissolved and gaseous oxygen can penetrate through more than 700  $\mu\text{m}$  of intact human skin, including the epidermis.<sup>10</sup> In open wounds where epi-

dermis is eroded, oxygen has been detected 2 mm below the surface of the wound.<sup>11</sup> Administration of topical oxygen increased PO<sub>2</sub> from 5 to 7 mm Hg to more than 40 mm Hg in the center of full-thickness excisional wounds in pigs.<sup>11</sup> In other animal studies, epithelialization ( $P = .01$ )<sup>12</sup> and density of blood vessels<sup>11</sup> were significantly improved by the delivery of transdermal oxygen (100%) to the wounded area. Gordillo<sup>13</sup> evaluated topical oxygen for the treatment of chronic wounds in the trunk or lower extremities. Twenty-five patients received standardized topical oxygen treatment for 90 minutes per day for 4 consecutive days a week for 14 weeks. Topical oxygen was associated with an induction of VEGF expression in wound-edge tissue ( $P = .031$ ) and an improvement in wound volume ( $P = .001$ ). The majority of the wounds were classified as surgical; results may not be generalizable to other chronic wound types. In a study of venous leg ulcers, Tawfik and Sultan<sup>14</sup> demonstrated that 80% of the subjects achieved complete wound closure with topical oxygen and compression as opposed to only 35% using compression alone ( $P < .0001$ ). Median time to wound closure was reduced to 45 days by combining topical oxygen and compression versus 182 days with conventional compression alone ( $P < .0001$ ). Topical oxygen was delivered from a piped wall outlet at a flow rate of 10 L/min into a sealed chamber within which subjects were requested to place their affected limb for 180 minutes twice a day up to 12 weeks. A portable device is commercially available (EPIFLO; Ogenix Corporation, Ft Lauderdale, Florida) to allow patients to remain ambulatory and continue normal daily living activities, while being treated 24 hours per day. Hypothetically, continuous application of oxygen to wounds may be more advantageous to healing. In the absence of evidence, findings from studies of intermittent topical oxygen therapy should not equate with those from studies of continuous oxygen therapy. In a case series, Hirsh et al<sup>15</sup> evaluated the use of transdermal sustained oxygen therapy in 6 patients with diabetic foot ulcers. The small portable device delivered oxygen continuously while patients carried out their normal daily living activities without interruption. Five of 6 wounds were healed between 2 and 20 weeks of treatment.

The purpose of this study was to evaluate the application of transdermal continuous topical oxygen therapy (TCOT) to promote healing in chronic wounds.

## TRANSDERMAL OXYGEN THERAPY

EPIFLO consists of a disposable electrochemical membrane (Figure 2) with no moving parts and weighing 4 oz. It silently delivers 3 mL/h of oxygen directly into the wound bed providing treatment continuously through a 60-in cannula.

The heart of the device consists of a membrane electrode assembly made with perfluorosulfonic acid cation exchange membrane (Nafion; DuPont, Wilmington, Delaware) that allows

hydrogen ion transport. This membrane is sandwiched between 2 electrodes. As the ambient air enters the device reaching the cathode, the oxygen molecule is reduced to water after a chemical reaction with the protons in the membrane and the electrons supplied from the power source. Water travels through the cation exchange membrane to the opposite electrode (anode) and dissociates into oxygen and protons.

## METHODS

In this case series, 9 patients with chronic ulcers in the lower extremities were treated with continuous transdermal oxygen therapy. All patients were recruited from an ambulatory wound clinic in Toronto. To be part of the study, all wounds were at least 1 cm<sup>2</sup> and at least 1 month in duration. To rule out arterial insufficiency that may impair wound healing, all patients had either a palpable pulse (approximately  $\geq 80$  mm Hg), ankle brachial index (ABI) greater than 0.65, or a toe pressure greater than 50 mm Hg. In addition, compression therapies were instituted for the appropriate patients with leg ulcers (ABI of  $>0.65$ ), and proper pressure downloading devices were prescribed for patients with diabetic foot ulcers.

### Ethical Approval

This study was approved by an independent research ethics board. Written informed consents were obtained from all participating subjects.

### Study Protocol

Wounds were adequately debrided prior to the initiation of the study. To ensure optimal delivery of topical oxygen, the tip of the cannula was placed in the middle of the wound resting directly

on top of the wound bed. Appropriate moisture-absorbing dressings were then applied to cover the wound and cannula. Small pieces of dressing materials were placed beneath the length of the cannula to avoid potential pressure and trauma to the wound bed and periwound area. A secondary dressing and adhesives were used to ensure that the wound edges were sealed to create an occlusive environment and avoid oxygen leakage. Dressings were applied 2 to 3 times a week (usually by home-care nurses to ensure treatment adherence) for a period of up to 4 weeks. Patients were instructed that oxygen flow would not be impeded even when the cannula was bent. However, at least one of the intake seams on the portable device should be unobstructed to allow air circulation. Because this portable device depends on the availability of sufficient air to conduct the concentration process, it ensured that at least one of the air-intake seams remained unobstructed. Follow-up evaluations were conducted by the research team at weeks 2 and 4 (the final visit). The ulcer characteristics, wound surface area, periwound skin condition, and pain levels were documented at each visit (baseline/week 0, week 2, week 4). Wound swabs were obtained after cleansing and debridement using the Levine technique at weeks 0 and 4 for quantitative culturing. Although other topical antimicrobial agents and cleansing solutions were excluded, systemic antibiotics were prescribed for the treatment of deep infection as needed.

### Wound Surface Area

The percentage decrease in wound surface area was calculated by measuring the wound surface area during each study visit (week 2, week 4) and comparing that visit's value with the baseline wound measurement (week 0). Wound surface areas were measured by multiplying the longest length by the widest width that were perpendicular to each other (length  $\times$  width = cm<sup>2</sup>).

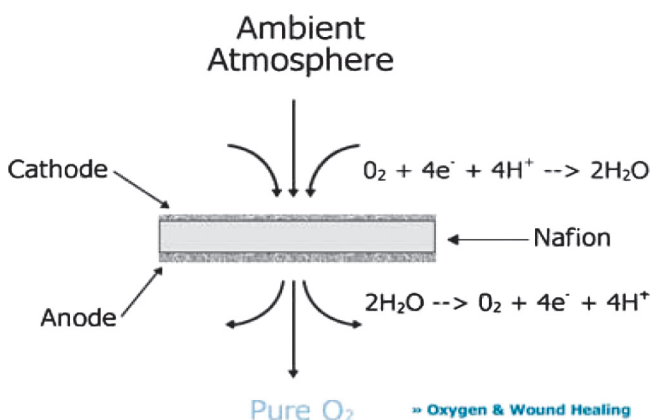
### Wound Assessments

Characteristics of the wounds were documented using a checklist based on clusters of clinical signs that are associated with superficial and deep wound infection.<sup>16</sup> Ten parameters were developed to include the evaluation of Unhealthy tissue, Pain, Poor healing, Exudate, and Reek (UPPER) for superficial wound infection versus Larger size, Osseous tissue, Warmth, Edema, and Redness (LOWER) for deep wound infection (Table 1). Each item was rated on a Likert scale of 0 to 2 to indicate the severity of the observed sign. The infection checklist scores can range from 0 to 30; the higher the scores, the more likely the presence of wound infection.

## RESULTS

Nine subjects with lower-extremity ulcers completed all study visits. Overall, 82% of these subjects were male with a mean age

**Figure 2.**  
TOPICAL OXYGEN PRODUCED BY CATION  
EXCHANGE MEMBRANE



**Table 1.****Wound infection checklist: UPPER and LOWER**

Baseline Parameters	0	1	2	3	Instruction
UPPER: localized superficial wound infection					
Unhealthy tissue	None	<25%	26%–50%	>50%	Document the amount of discolored/friable granulation tissue and nonviable tissue
Pain	No			Yes	Document pain
Poor healing	Decrease by >10%	Decrease by <10%	Same size	Larger	Compare wound size measurement obtained at baseline
Exudate	None/scanty (0%–15%)	Light (15%–35%)	Moderate (35%–65%)	Heavy (65%–100%)	Document the area of the dressing saturated/stained by exudate
Reek	None			Present	Document if odor is present or not
LOWER: deep wound infection					
Larger and new areas of breakdown	No			Yes	Document areas of breakdown and size increase
Os: probe to bone	No	Probe to periosteum	Yes but firm	Yes and gritty	Determine if bone can be probed and describe the characteristics
Warmth: infrared thermometry	<2°F	2°–4°F	4°–6°F	>6°F	Compare periwound temperature with the mirror image sites on the contralateral side
Edema (localized)	None	Mild	Moderate	Severe	Document the severity of edema
Redness (margin)	None	Mild	Moderate	Severe	Document the severity of redness

of 53.89 years (range, 43–72 years). The mean surface area reduced from 12.03 cm<sup>2</sup> at baseline to 9.60 cm<sup>2</sup> at week 4. The difference in surface area was significant ( $t_8 = 3.04$ ,  $P = .016$ ). The wound infection checklist score was reduced from 5.3 to 2.7 ( $t_8 = 3.8$ ,  $P = .027$ ) in the first 3 weeks of therapy, indicating improvement in wound characteristics that were associated with infection. The numbers of patients exhibiting 3 or more clinical signs indicating bacterial damage were reduced from 6 at the beginning of the study to 3 at week 5. All patients except patient 009 received antibiotic treatment during the study (Table 2).

## DISCUSSION

Results of this case series of patients with chronic wounds in the lower extremities suggest that transdermal continuous oxygen may promote healing of chronic wounds. Mean wound surface areas were significantly reduced from 12.03 to 9.60 cm<sup>2</sup> over the 4 weeks

of observation. Local wound assessment of physical signs that were related to wound infection (UPPER and LOWER) also improved significantly. It is well established that the diagnosis of infection is rendered based on clinical evaluation. To standardize the diagnostic approach, the wound infection checklist, including 10 observable signs, was developed to determine the presence of wound infection. These clinical signs were originally described by Sibbald et al<sup>16</sup> and validated in a study of 92 patients with chronic leg and foot ulcers.<sup>17</sup> Unhealthy wound tissue and increased exudate were found to be 5 times more likely to be associated with local wound infection, whereas wounds with increased warmth were 8 times more likely to be a result of deep infection according to bacteriology findings from semiquantitative swabs. There is no single sign that is sufficient to confirm wound infection, but an affirmative identification of a cluster of signs may improve the diagnostic accuracy. The sensitivity of using any 3 clinical signs to

**Table 2.****Subjects and wound characteristics**

ID	Age	Location	Causes	Wound Size, cm		Wound Infection Score	
				Baseline	Visit 5	Baseline	Visit 5
001	45	Left lateral malleolus	PSU	3 × 2.5	2.1 × 2.5	11	5
002	63	Left pretibial	VLU	4.9 × 4.9	4.8 × 4	4	5
003	55	Left lateral foot	DFU	2.9 × 2.4	2.6 × 1.6	7	3
004	43	Left popliteal fossa	PSU	9.5 × 4.5	8.4 × 5	3	3
005	59	Right metatarsal head	DFU	2 × 1.9	1.7 × 1	4	3
006	46	Right ankle	DFU	0.6 × 1	0.9 × 0.4	2	5
007	53	Left pretibial	VLU	4 × 2.7	3.2 × 1	6	2
008	72	Right medial malleolus	VLU	5.3 × 2	4.8 × 2.1	7	3
009	49	Right lateral pretibial	VLU	1.3 × 1	0.6 × 0.7	4	3

Abbreviations: DFU, diabetic foot ulcer; PSU, postsurgical ulcer; VLU, venous leg ulcer.

determine the presence of wound infection in the upper and lower compartment was 73.3% and 90%, respectively, compared with the specificity of 80.5% and 69.4%. In the present case series, the number of patients exhibiting the critical level of at least 3 clinical signs associated with wound infection had reduced over time with TCOT. Because local wound infection can delay wound healing, it is logical to surmise that continuous transdermal oxygen therapy may reduce bacterial burden, allowing wound healing to occur. Oxygen is an essential substrate for the production of reactive oxygen species including  $H_2O_2$  and superoxide that exert potent antimicrobial activities.<sup>6</sup> Wound infection rate was reduced by half in surgical patients who received 80% of supplemental oxygen compared with those who received only 30% of oxygen during and 2 hours after colonic resections.<sup>18</sup> In another study of 130 general surgical patients,<sup>19</sup> oxygen tension of the subcutaneous tissue is predictive of wound infection. This study is limited by a small sample ( $n = 9$ ) with multiple wound types without a control group for comparison. Although glycosylated hemoglobin was evaluated prior to subjects entering into the study to ensure optimal glycemic control for wound healing, the adequacy of glycemic control during the study was not known. Other confounding variables may include the wide range of age, coexisting medical problems, and medications. Randomized controlled trial is required to validate findings of this study in the future. Existing evidence indicates that systemic oxygen through HBOT may be able to promote healing of arterial ulcers by raising  $PaO_2$ . However, findings of the current study and other emerging studies demonstrate that TCOT may be beneficial in combating wound infection and enhancing angiogenesis. Outcomes of the therapy may be dependent on the continuous supply of oxygen to wounds at every phase of wound healing; intermittent use of topical oxygen may not achieve a similar outcome. In selected patients with chronic wounds and appropriate indications, TCOT may be a more cost-effective alternative to HBOT or to intermittent topical oxygen. ●

## REFERENCES

1. Woo K, Ayello EA, Sibbald RG. The edge effect: current therapeutic options to advance the wound edge. *Adv Skin Wound Care* 2007;20:99-117.
2. Sibbald RG, Williamson D, Orsted HL, et al. Preparing the wound bed—debridement, bacterial balance and moisture balance. *Ostomy Wound Manage* 2000;46(11):14-22, 24-8, 30-5.
3. Sibbald RG, Woo KY, Queen D. Wound bed preparation and oxygen balance—a new component? *Int Wound J* 2007;Suppl 3:9-17.
4. Rodriguez PG, Felix FN, Woodley DT, Shim EK. The role of oxygen in wound healing: a review of the literature. *Dermatol Surg* 2008;34:1159-69.
5. Akça O, Melischek M, Scheck T, et al. Postoperative pain and subcutaneous oxygen tension. *Lancet* 1999;354(9172):41-2.
6. Gordillo GM, Sen CK. Evidence-based recommendations for the use of topical oxygen therapy in the treatment of lower extremity wounds. *Int J Low Extrem Wounds* 2009;8:105-11.
7. Heng MC, Harker J, Bardakjian VB, Ayvazian H. Enhanced healing and cost-effectiveness of low-pressure oxygen therapy in healing necrotic wounds: a feasibility study of technology transfer. *Ostomy Wound Manage* 2000;46(3):52-60, 62.
8. Ruangsetakit C, Chinsakchai K, Mahawongkajit P, Wongwanit C, Mutirangura P. Transcutaneous oxygen tension: a useful predictor of ulcer healing in critical limb ischaemia. *J Wound Care* 2010;19(5):202-6.
9. Bennett MH, Feldmeier J, Hampson N, Smee R, Milross C. Hyperbaric oxygen therapy for late radiation tissue injury. *Cochrane Database Syst Rev* 2005;(3):CD005005.
10. Roe DF, Gibbins BL, Ladizinsky DA. Topical dissolved oxygen penetrates skin: model and method. *J Surg Res* 2010;159(1):e29-36.
11. Fries RB, Wallace WA, Roy S, et al. Dermal excisional wound healing in pigs following treatment with topically applied pure oxygen. *Mutat Res* 2005;579(1-2):172-81.
12. Said HK, Hijawi J, Roy N, Mogford J, Mustoe T. Transdermal sustained-delivery oxygen improves epithelial healing in a rabbit ear wound model. *Arch Surg* 2005;140:998-1004.
13. Gordillo GM, Roy S, Khanna S, et al. Topical oxygen therapy induces vascular endothelial growth factor expression and improves closure of clinically presented chronic wounds. *Clin Exp Pharmacol Physiol* 2008;35:957-64.
14. Tawfik W, Sultan S. Does topical wound oxygen (TW02) offer an improved outcome over conventional compression dressings (CCD) in the management of refractory venous ulcers (RVU)? A parallel observational comparative study. *Eur J Vasc Endovasc Surg* 2009;38(1):125-32.
15. Hirsh F, Berlin SJ, Holtz A. Transdermal oxygen delivery to diabetic wounds: a report of 6 cases. *Adv Skin Wound Care* 2009;22:20-4.
16. Sibbald RG, Woo K, Ayello EA. Increased bacterial burden and infection: the story of NERDS and STONES. *Adv Skin Wound Care* 2006;19:447-61.
17. Woo KY, Sibbald RG. A cross-sectional validation study of using NERDS and STONES to assess bacterial burden. *Ostomy Wound Manage* 2009;55(8):40-8.
18. Greif R, Akça O, Horn EP, Kurz A, Sessler DI. Outcomes Research Group. Supplemental perioperative oxygen to reduce the incidence of surgical-wound infection. *N Engl J Med* 2000;342:161-7.
19. Hopf HW, Hunt TK, West JM, et al. Wound tissue oxygen tension predicts the risk of wound infection in surgical patients. *Arch Surg* 1997;132:997-1004.

Get fast news updates on the latest developments  
in the skin and wound care field.

Advances in

SKIN & WOUND CARE

eNEWS

Sign up for our free monthly eNews and we'll send you cutting edge information on what's new in skin and wound care, plus we'll include free links to Bonus Content and CME articles.

It's easy and it's free. To register, visit <http://www.nursingcenter.com/aswcenews>